

Extracapsular Suture (ES)

Stabilization for Cranial Cruciate Ligament Tears using the Lateral Suture(s) Technique

Introduction

Surgical stabilization of dogs having a tear of the cranial cruciate ligament is recommended unless anesthesia or surgery are contraindicated due to concurrent medical conditions. Extracapsular and intracapsular techniques are described to stabilize the cruciate-deficient stifle. An extracapsular method of stabilizing the joint is the most common technique used by general practitioners due to its simplicity and cost. Extracapsular repair techniques have been available for over 50 years, and over 200 technique variations have been described. Extracapsular techniques include imbrications, prosthetic ligament substitute substitutes (including suture), tibial plateau leveling osteotomy (TPLO), tibial tuberosity advancement (TTA), cranial closing wedge osteotomy (CCWO) and fibular head transposition. The stabilization method herein described includes a prosthetic ligament substitute (suture) technique. This technique does not repair the CCL or replace it, but rather, stabilizes the stifle during which time natural fibrosing of adnexial tissue ‘assumes the load’ for stability.

Step by Step Instructions

1. Surgical Approach

The patient is placed in dorsal recumbency or lateral recumbency with the operated leg up, and a standard lateral parapatellar approach is recommended. A curvilinear skin incision is made, centered over the lateral aspect of the stifle.

The subcutaneous tissues and deep fascia are incised on the same line. A lateral arthrotomy is performed and the patella is medially luxated to allow visualization of the joint. Luxation of the patella is facilitated by use of a Gelpi retractor and incising the joint capsule to its most proximal extent. A Senn retractor is used to retract the patellar fat pad distally for improved visualization.

2. Stifle Exploration

The leg is ideally held in flexion by an assistant and positioned such that the surgeon is looking at the stifle end-on. At this point a quality headlamp is considered by many surgeons to be an essential item for the procedure. The intra-articular structures are identified and evaluated. The cranial cruciate ligament (CrCL) is assessed with respect to normal, partial tear or complete tear. The caudal cruciate should be assessed similarly. Remnants of the torn cranial cruciate ligament (CrCL) are removed using a #11 blade. (Retained ligament is considered by some to be a chronic source of inflammatory mediators.) Articular surfaces should be assessed as normal, or with fibrillation, partial thickness erosion or full thickness erosion. Osteophyte presence is graded as none, mild, moderate or severe.

Meniscal assessment is enhanced with the use of a Hohmann retractor and headlamp. The medial and lateral menisci are assessed for tears. A bucket-handle tear of the medial meniscus is the most common tear. A partial meniscectomy is performed if a meniscal tear is present. Assess the patella for erosion and the patellar groove for adequate depth.

CONTINUED ON NEXT PAGE

3. Stifle Stabilization

A. Material used for prosthetic ligament substitute

A prosthetic ligament substitute will be used to stabilize the joint and simulate the actions of the original CrCL. In this description, the prosthetic ligament substitute is composed of monofilament suture material. The preferred type of monofilament is a heavy monofilament leader line. This leader line is stiff and will not stretch (creep) to the extent noted with regular monofilament. A variety of sizes are available. SECUROS recommends 100, 80, or 40 pound test; depending upon patient size. OrthoFiber, a braided polyblend, is an additional option; available for patients weighing 95 pounds and less. A rule of thumb is to use a pound of test suture most closely matching the patient's weight. Pre-sterile suture materials are proposed so as to avoid suture weakening by autoclaving.

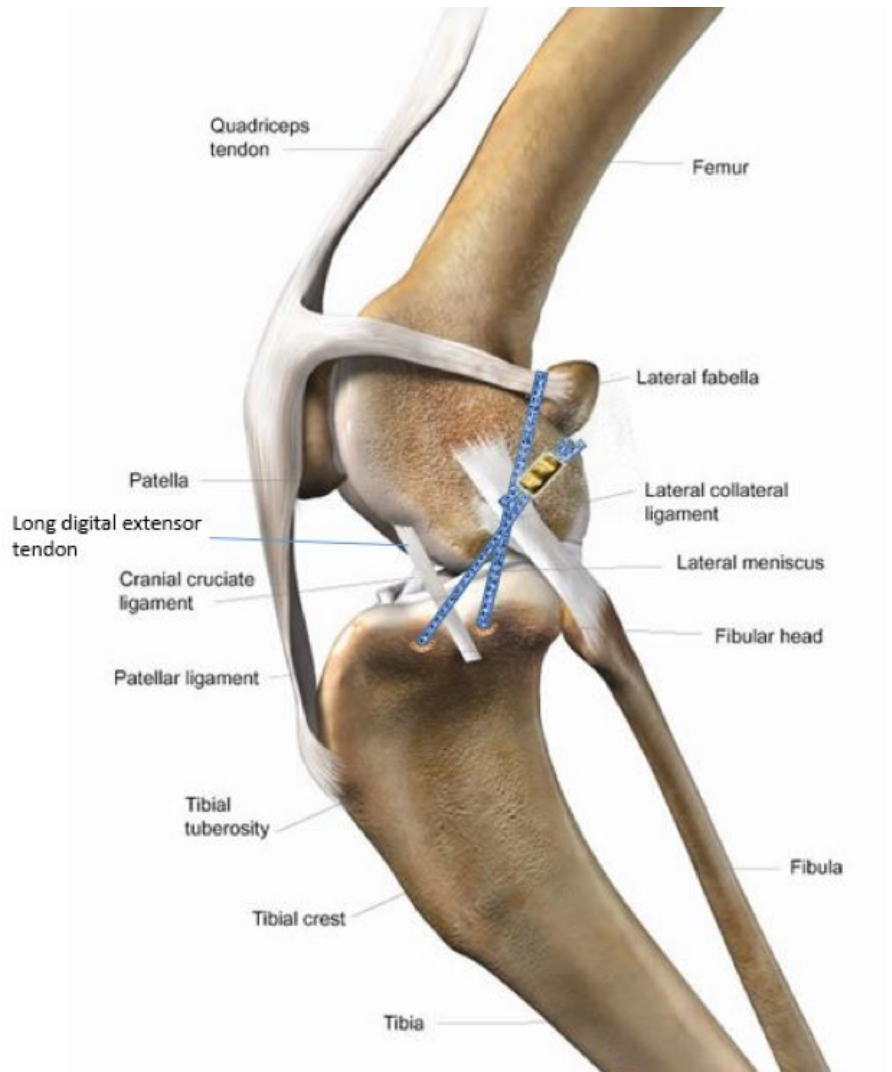
B. Location of prosthetic ligament substitute

It is important to place the prosthetic ligament substitute as isometric as possible. Isometric positioning will maintain similar tension on the substitute ligament throughout the joint's range of motion, will decrease the chance of stretching or breaking the ligament, and will allow more normal movement of the stifle.

A recent study assessed isometric positioning of a lateral extracapsular suture anchored to the lateral femoral condyle and the proximal tibia. The points of attachment associated with the most isometric placement are:

proximal attachment- at the origin of the lateral collateral ligament on the lateral femoral condyle. This site is located at the caudal extent of the condyle and at the same level as the distal pole of the lateral fabella of the gastrocnemius muscle. Attachment around the lateral gastrocnemius fabella is also an acceptable position.

distal attachment- at the proximal tibia, just caudal or cranial to the long digital extensor tendon.



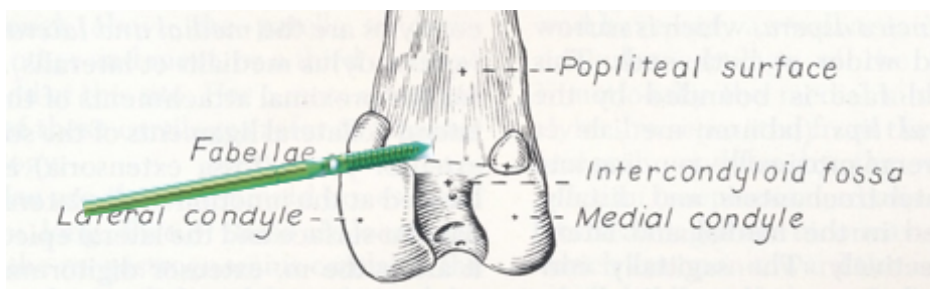
CONTINUED ON NEXT PAGE

C. Attachment of the prosthetic ligament substitute

The prosthetic ligament substitute can be anchored in traditional fashion around the lateral gastrocnemius fabella, which is adjacent to the isometric location identified in the lateral femoral condyle. Attachment of the prosthetic ligament substitute directly to the lateral femoral condyle is accomplished using a bone anchor.

Hereafter is described use of a bone anchor for recommended attachment of the prosthetic ligament substitute. The SECUROS® Bone Anchor (SECUROS, Fiskdale, MA) has been used for several decades to stabilize cruciate-deficient stifles in dogs. The 3.5mm size anchor is generally used for this application, however, the 2.7mm anchor is recommended for dogs weighing less than 40 pounds.

The 3.5mm anchor is loaded into a hand chuck with the suture material of choice and is inserted into a pre-drilled 3.2mm hole within the lateral femoral condyle. (Pre-drilling is highly recommended, as is countersinking the hole.) Optimal placement of the bone anchor (for isometry) is near the lateral fabella in the lateral epicondyle of the femur. This structure narrows in thickness from anterior to posterior; therefore the pilot hole should not be drilled perpendicular to the lateral surface of the femur, but rather, directed in a proximal-anterior direction so as to engage substantive metaphyseal bone.



The 3.5mm anchor will accommodate 1 strand of 80# monofilament nylon. The 4.5mm anchor will accommodate 2 strands of 80# monofilament or 1 strand of 100# monofilament nylon. Instrumentation is minimal (hand chuck) and placement of the anchor (caudal aspect of the lateral femoral epichondyle) is relatively simple.

The prosthetic ligament substitute is anchored to the proximal tibia using a bone tunnel technique. Two bone tunnels are formed by drilling two 3.2mm holes across the tibial tuberosity using a pin or drill bit. The ligament is passed lateral to medial through one hole and medial to lateral through the second hole.

The stifle should be positioned at a weight-bearing angle (approximately 135 degrees). The suture is tensioned with the aid of the Securos Universal Tensioning Device, and is crimped using a stainless steel crimp clamp.

The prosthetic ligament substitute should be tensioned enough to eliminate cranial drawer motion; remaining taught through a full stifle range of motion. Over tensioning will constrain stifle range of motion, place excessive stress on the suture, and lead to premature ligament failure. It is worthy of note that suture used for CrCL stabilization will not maintain its integrity indefinitely. Its role is to maintain joint stability until such time as tissue fibrosis can accept the load.

CONTINUED ON NEXT PAGE

D. Postoperative Period and Rehabilitation

A soft-padded bandage can be placed for 2-5 days to reduce swelling, decrease pain, and prevent self-trauma to the incision. Prolonged bandaging is inappropriate. Early return to weightbearing and light activity is encouraged; initially limited to short, slow walks and passive range of motion exercise. Rehabilitation ideally should incorporate strength, postural, and flexibility exercises. Return to full activity is generally constrained for approximately 4-5 months.

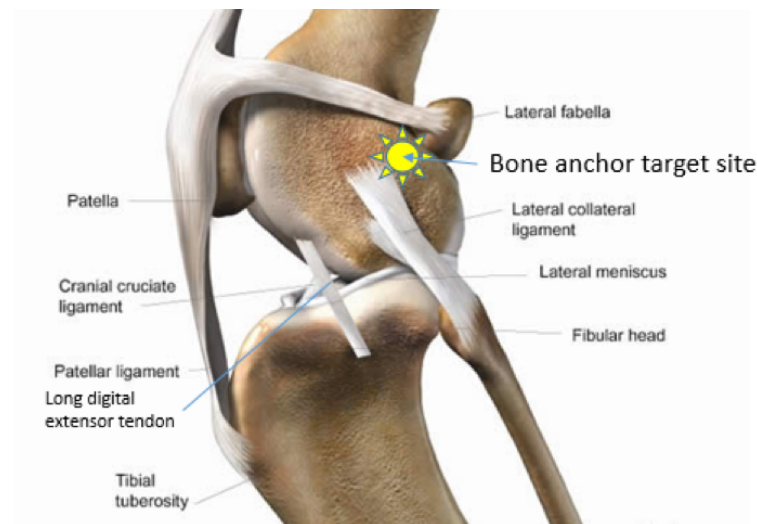
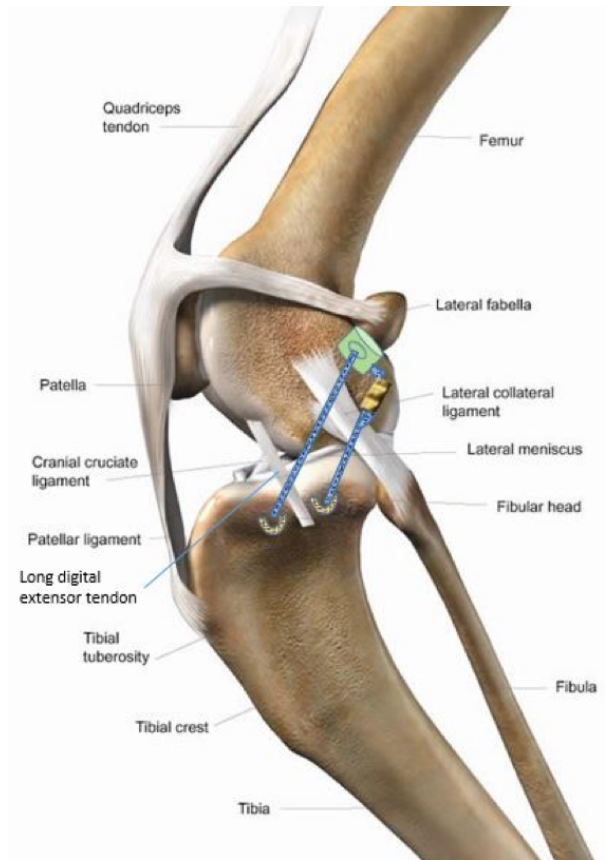
Securos Bone Anchor Technical Analysis

The SECUROS anchors have a relatively large eyelet and the edges of the eyelet have been rounded to prevent suture abrasion. Monofilament nylon is more resistant to cyclic loading than braided suture, since individual strands cannot be serially abraded.

The SECUROS bone anchor holding strength was not affected by cyclic loading, and holding strengths of approximately 385N can be expected in metaphyseal bone of large breed mature dogs.

Study findings:

- Longitudinal holding strength in the femur: 538±125N
- Longitudinal holding strength in proximal humerus: 385±30N
- Anchors in the humeri did not fail after 1200 cycles of 50% longitudinal loading
- Post holding strength was not affected: 335±87N
- Perpendicularly loaded anchors did not fail after 1200 cycles of 100% of opposite longitudinal holding strength
- Post cycle perpendicular holding strengths: 514±72N



Conclusions: The Securos bone anchor holding strength is not affected by cyclic loading, and holding strength ranging from 335N to 538N can be expected in metaphyseal bone of large breed dogs in relation to orientation.



Bone Anchors

Securos Surgical offers two bone anchor designs in various sizes, metal composition and lengths: (1) break-off bone anchors (stainless steel or titanium), and (2) box head anchors (stainless steel).



Product Instructions

The SECUROS Bone Anchor is a simple and effective device for securing suture (including monofilament nylon) to bone. Surgical applications may include:

- Attaching monofilament nylon or braided suture (Orthofiber) adjacent to the fabella (instead of passing suture around the fabella) in the extracapsular suture (ES) techniques of cruciate ligament stabilization.
- Securing collateral ligaments in the repair of joint luxations (elbow, stifle, hock, etc.)
- Stabilization of hip luxations using the synthetic capsule technique
- Stabilization of shoulder instabilities, including tears of the medial glenohumeral ligament.
- Reattaching tendon avulsions or tendon transection such as infraspinatus transection used in the approach to the humeral head for OCD curettage.

The break-off anchor is composed of a trocar point, cortico-cancellous thread section, suture spindle (with variable-sized hole), break-off point, and an insertion shaft. *Countersinking the anchor is suggested to minimize potential abrasion of the suture by the drilled bone edge. Once the anchor is placed, the application shaft separates at the break-off point. The shaft is discarded while the spindle and threaded portion, with your choice of threaded suture material, remains firmly embedded in bone.

Application only requires a hand chuck and a 2.4mm or 3.2mm drill bit. SECUROS highly recommends pre-drilling all anchor sites.

Anchor Size (mm)	Drill Bit (mm)	Suture Size (#)	Patient Weight (lbs)
2.7	2.4	40	0-30
3.5	3.2	80	30-70
4.5	3.2	80 / 100	>70

CONTINUED ON NEXT PAGE



Securos Surgical sold exclusively through MWI Animal Health

800.824.3703

Service Support: 877.266.3349

mwiah.com

securos.com

We build *our* work around the way *you* work.

Application in the cancellous metaphyseal area of long bones

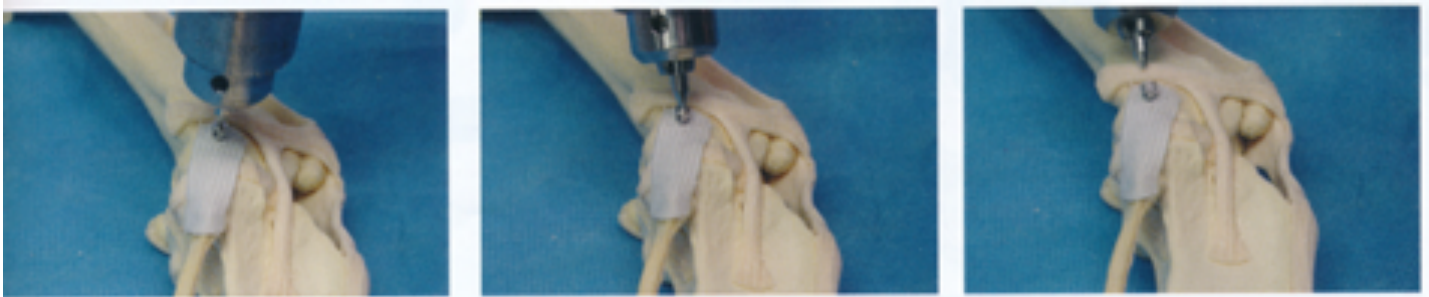(such as an anchor for the lateral suture technique for cranial cruciate stabilization)

1. **3.5mm & 4.5mm Bone Anchors:** Drill a 3.2mm hole approximately 15mm (1/2 inch) deep. Countersinking is suggested.
2.7mm Bone Anchor: Drill a 2.4mm hole approximately 15mm (1/2 inch) deep. Countersinking is suggested.
2. Place the insertion shaft of anchor into the pin chuck.
3. Place your choice of suture material through the hole in the anchor.
4. Using the pin chuck, screw the anchor to desired depth.
5. If the insertion point is firm bone, oscillate the pin chuck from side to side to break off the insertion shaft. If the insertion point is soft bone or comprised of limited bone stock, (often the case in miniature breeds), use a pin cutter to avoid the potential for iatrogenic fractures.

Application in dense cortical bone

(such as head of the radius or condyle of the humerus in collateral ligament reconstruction)

1. **3.5mm & 4.5mm Bone Anchors:** Drill a 3.2mm hole approximately 15mm (1/2 inch) deep. Countersinking is suggested.
2.7mm Bone Anchor: Drill a 2.4mm hole approximately 15mm (1/2 inch) deep. Countersinking is suggested.
2. Place the anchor into the pin chuck, ensuring that the entire anchor spindle is grasped. Failure to include grasping of the spindle may result in premature breaking-point separation from the torque of insertion.
3. Once the anchor is approximately halfway inserted, remove the pin chuck and insert the suture into the anchor.
4. Re-grasp at the insertion shaft and complete insertion. Break off the insertion shaft.



After predrilling and countersinking the hole, place the anchor and bend the anchor insertion shaft until breaking.

CONTINUED ON NEXT PAGE

Frequently asked questions about bone anchors:

Why is the suture spindle shaped as it is?

The spindle is designed to hold the suture without breakage in cyclic loading. It will accommodate either braided suture (up to #5 polyester) or up to 100-pound tensile monofilament nylon, depending on the size of the bone anchor. When using braided suture in collateral ligament reconstructions, the suture can be placed in the spindle with a single throw (half of a square knot) in the groove to dramatically increase suture/anchor strength. The edges of the suture hole are rounded to minimize suture breakage.

Why do I need to pre-drill when there is a trocar point on the anchor?

Pre-drilling with the appropriately sized drill bit, whether it is for a bone screw, external fixation pin, or bone anchor is always a good idea. The trocar tip of the anchor will drill into bone, but it primarily acts to tap the screw threads. The harder the bone the more important it is to pre-drill. Using the trocar point of the anchor to drill the hole may prematurely break the insertion shaft, especially if the suture spindle is not included within the jaws of the chuck.

Can I use the bone anchor with the SECUROS Cruciate Repair System?

Absolutely! Place the bone anchor just distal and cranial to the fabella. This will place the origin of the lateral suture in the optimal isometric point of the femur. Countersink the head of the bone anchor into the fascia and direct the anchor toward the medial epicondyle to engage the best metaphyseal bone stock. Use the crimp system just as you would when passing the suture around the fabella.

Do I leave the suture spindle above the surface of the bone, or insert the anchor until I can't see it anymore?

Either positioning is acceptable. When using the anchor with the lateral suture technique for cruciate stabilization, the suture spindle may be countersunk within the fascia and distal femur periosteum. In collateral ligament reconstruction, the spindle head is often left 'proud' so that suture can be wrapped and tied around the spindle.

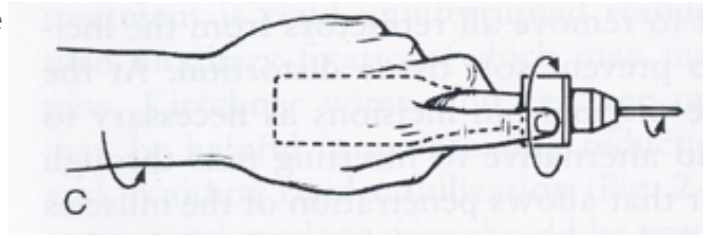
When I rock the pin chuck back and forth to remove the insertion shaft, the bone around the anchor seems to crack. Is this OK?

No. This 'cracking' is a signal of microfractures. In most cases, this indicates the bone into which you are inserting the anchor is soft and may not be strong enough for an anchor, screw or any other orthopedic device. Arguably, this is a consideration in the use of bone anchors for miniature breeds. Consider alternative methods such as bone tunneling. If you insist on the use of bone anchors in these high-risk cases, after insertion, cleave the insertion shaft at the break-off point with a pin cutter.

CONTINUED ON NEXT PAGE

When I am inserting the bone anchor, the insertion shaft breaks off before I completely sink the anchor. What can I do to avoid this?

First, make sure you are pre-drilling the hole with an appropriate sized drill bit. Second, use the “Application in dense cortical bone” insertion technique (above). This gets the anchor started, after which it should screw in easily. Third, make sure you are inserting the anchor with correct chuck technique, i.e., without undue wobble to your pin chuck.



To minimize chuck wobble, grasp the chuck as depicted, lock the wrist and drive the screw/pin/anchor (oscillating pronation and supination if placing a pin) as if the forearm were a single anatomic structure from elbow to finger tip.

I used the suture anchor as directed and surgery went well. However the suture broke at the anchor prematurely. What went wrong?

The anchor will hold the suture at near its tensile strength for thousands of cycles. Once the force on the suture reaches its tensile strength, it will usually break at the spindle. Ensure that the appropriately sized suture is being used. If the largest suture is being used, support the repair with coaptation, if possible, and limit patient activity. In cruciate ligament stabilization, make sure your anchor points are isometric. Finally, beveling of countersinking holes helps to minimize a potential for suture abrasion and failure. It is worthy of note that suture used for CrCL stabilization will not maintain its integrity indefinitely. Its role is to maintain joint stability until such time as tissue fibrosis can ‘accept the load’.